

# Trachoma

## EPIDEMIOLOGY

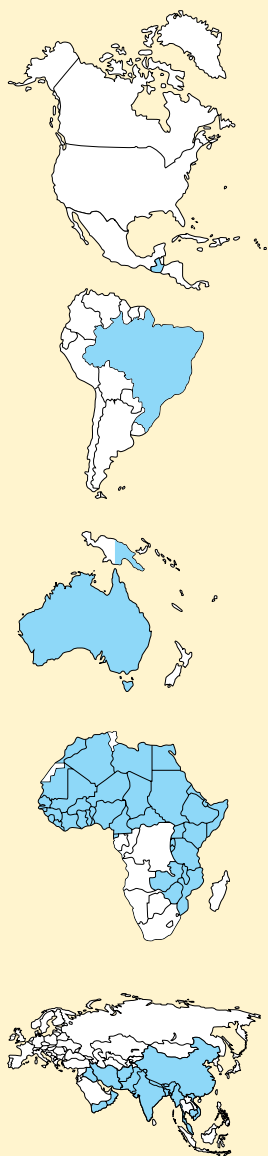Trachoma is caused by the obligate intracellular bacterium *Chlamydia trachomatis* and is the leading cause of preventable visual impairment globally. Distribution is worldwide, and disease occurs chiefly in poor communities in the tropics. Sub-Saharan Africa and Asia, parts of the Middle East, the Americas, and the Pacific Islands are most affected. Areas without clean water sources, with poor hygiene, and with crowded living conditions are at highest risk. More than 50 million people are infected with trachoma and between 3 and 10 million are blind as a result of the infection.

## PATHOPHYSIOLOGY

Vision loss in trachoma results from repeated ocular infections over many years. In endemic regions, most children are first infected by a year or two of life, and toddlers constitute the principal reservoir of *C trachomatis*. The organism is spread passively within a population by flies, fomites contaminated by secretions, or possibly aerosol droplets. The cycle of repetitive infections through childhood, adolescence, and adulthood causes progressive conjunctival scarring and corneal damage. During active infections, mucopurulent keratoconjunctivitis with follicular inflammation is typical. Individual episodes heal, but with repeated infections the conjunctival damage eventually results in entropion (inward turning of the eyelid) and trichiasis (continual eyelash irritation of the cornea). Scarring of the tarsal conjunctiva, chronic inflammation, ulceration, and corneal scarring define the cicatricial phase of disease. Neovascularization and the appearance of granulation tissue, or pannus, lead to corneal opacities. Complete blindness ultimately ensues, usually in the fourth or fifth decade.

## CLINICAL PRESENTATION

Up to three-quarters of children with active trachoma exhibit no symptoms. Active ocular infections are characterized by tearing, pruritis, edema, and pain. Lymphoid follicles become prominent whitish, yellow, or grey elevations. Inflammatory thickening and hyperemia of the conjunctivae are common, particularly under the tarsal plate. Depending on the frequency and severity of prior



Blue indicates areas of high risk.

infections, conjunctival scarring may be present and appears as white lines or patches on an erythematous background. Herbert pits are circular depressions at the limbus (the conjunctiva-cornea junction) and are the sequelae of earlier follicles that resolved with scarring.

Following the cicatricial phase, findings consistent with chronic trachoma include neovascularization and pannus originating at the limbus and extending into the cornea. Entropion and trichiasis are often plainly visible.

## DIAGNOSIS

---

Trachoma is diagnosed on clinical grounds when any of the following are present:

1. Five or more follicles  $> 0.5$  mm in diameter on tarsal conjunctivae
2. Conjunctival scarring
3. Limbal follicles or Herbert pits
4. Corneal neovascularization and granulation tissue formation

During the active stage of infection, diagnosis is confirmed by demonstrating pathognomonic inclusion bodies in Giemsa-stained scrapings from tarsal follicles. Inclusion bodies appear as dark, intracellular, granular masses surrounding the epithelial cell

nucleus. Fluorescein antibody stains and serologic testing are also possible.

The World Health Organization classifies trachoma into the following 5 stages:

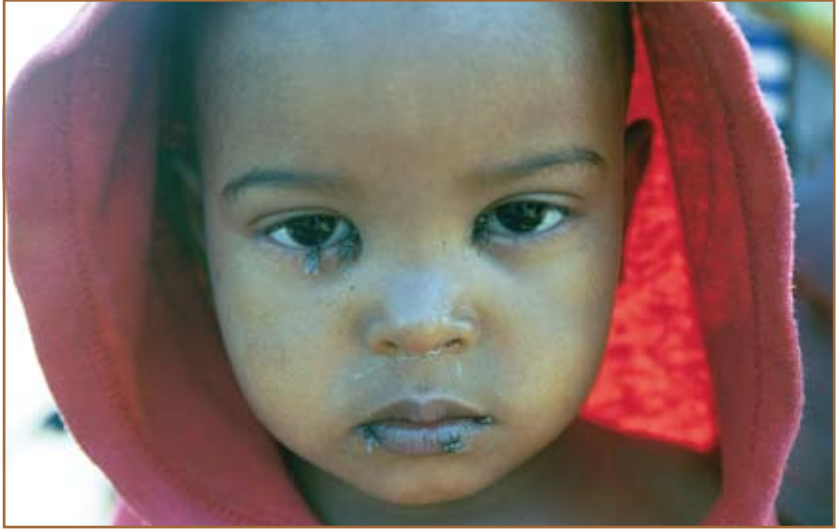1. Trachomatous inflammation follicular
2. Trachomatous inflammation intense
3. Trachomatous scarring of the tarsal conjunctiva
4. Trachomatous trichiasis
5. Trachomatous corneal opacity

## TREATMENT AND PREVENTION

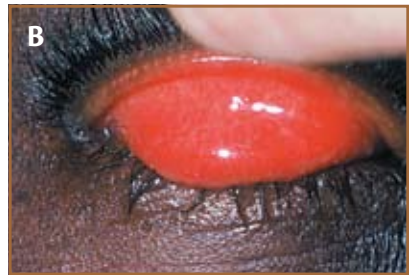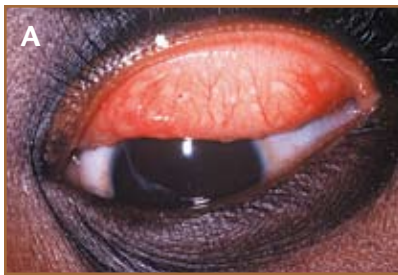---

The SAFE strategy encapsulates trachoma treatment and prevention objectives: Surgery for trichiasis, Antibiotic therapy, Facial cleanliness in young children, and Environmental improvements such as latrine building and improved access to water to reduce transmission. Single-dose azithromycin is the antibiotic of choice. Annual mass treatment of populations with moderate or high disease prevalence has been recommended to cure sufficient numbers of children such that the community's bacterial reservoir is reduced. With this approach, ocular infection rates in some regions have plummeted from 10% to 0.1% in as few as several years.

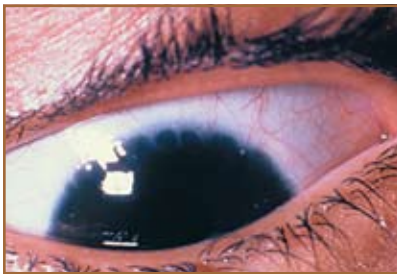---

**IMAGE 1**

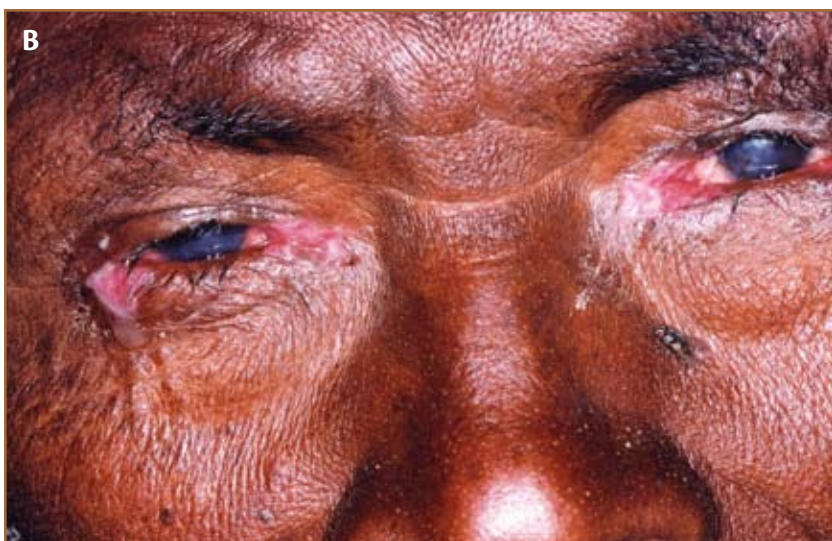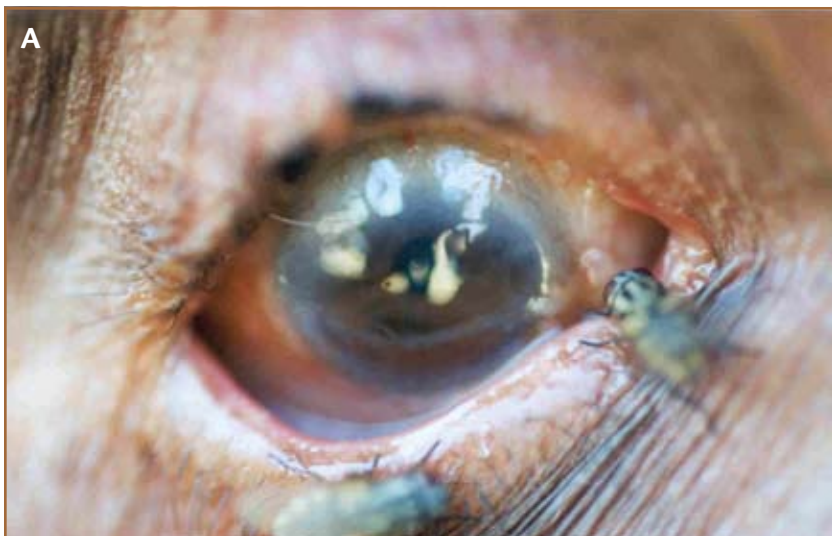Flies are not always benign creatures. The *Musca sorbens* insect vector, which breeds in human feces, transmits trachoma. *Courtesy: Elizabeth Gilbert, International Trachoma Initiative.*

**IMAGE 2A, 2B**

Progressive disease is characterized here by trachomatous inflammation (Image 2A) and a papillary reaction (Image 2B). *Courtesy: Larry Schwab from Eye Care in Developing Nations. 4th ed. London, UK: Manson Publishing Ltd; 2007.*

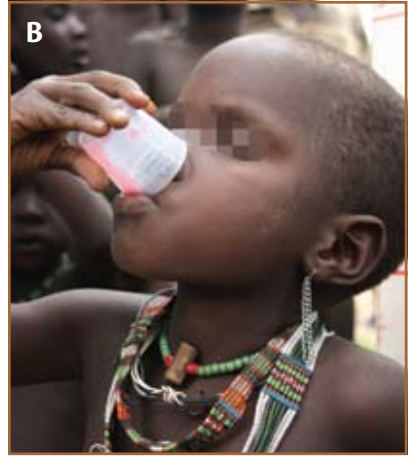

**IMAGE 3**

Shallow Herbert pits in the cornea follow follicle rupture and are considered to be pathognomonic for trachoma. *Courtesy: Larry Schwab from Eye Care in Developing Nations. 4th ed. London, UK: Manson Publishing Ltd; 2007.*



**IMAGE 4A, 4B**

Advanced stage trachoma (trichiasis) occurs when repeated infections scar the upper eyelid. The scars cause the lid to fold inward, making the lashes rub against the cornea with every blink, eventually leading to irreversible blindness. *Courtesy: The Carter Center.*

**IMAGE 5A, 5B**

Improved facial hygiene—even if only water is available—can prevent trachoma (Image 5A). A Sudanese girl takes a dose of banana-flavored azithromycin for protection against the bacteria that causes trachoma (Image 5B). Young children carry the highest burden of active trachoma infection and annual mass distribution of antibiotics has been recommended for communities where more than 10% of young children suffer from the disease. *Courtesy: Elizabeth Gilbert, International Trachoma Initiative (Image 5A) and The Carter Center/Paul Emerson (Image 5B).*



## IMAGE 6A, 6B

World Health Organization Trachoma Grading Card. *Courtesy: World Health Organization.*

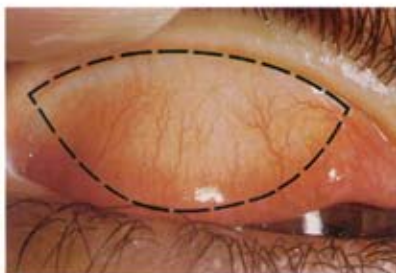A

## TRACHOMA GRADING CARD

- Each eye must be examined and assessed separately.
- Use binocular loupes (x 2.5) and adequate lighting (either daylight or a torch).
- Signs must be clearly seen in order to be considered present.

The eyelids and cornea are observed first for intumed eyelashes and any corneal opacity. The upper eyelid is then turned over (everted) to examine the conjunctiva over the stiffer part of the upper lid (tarsal conjunctiva).

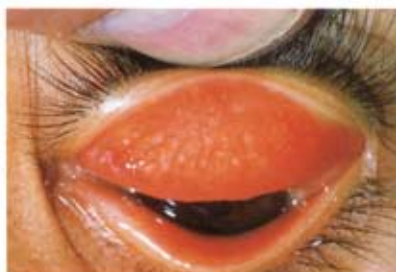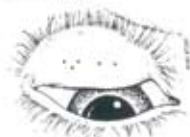The normal conjunctiva is pink, smooth, thin and transparent. Over the whole area of the tarsal conjunctiva there are normally large deep-lying blood vessels that run vertically.



*Normal tarsal conjunctiva (x 2 magnification). The dotted line shows the area to be examined.*

**TRACHOMATOUS INFLAMMATION – FOLLICULAR (TF):** the presence of five or more follicles in the upper tarsal conjunctiva.

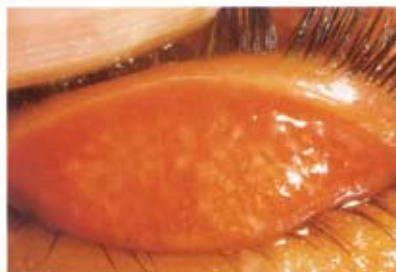Follicles are round swellings that are paler than the surrounding conjunctiva, appearing white, grey or yellow. Follicles must be at least 0.5mm in diameter, i.e., at least as large as the dots shown below, to be considered.



*Trachomatous inflammation – follicular (TF).*

**TRACHOMATOUS INFLAMMATION – INTENSE (TI):** pronounced inflammatory thickening of the tarsal conjunctiva that obscures more than half of the normal deep tarsal vessels.

The tarsal conjunctiva appears red, rough and thickened. There are usually numerous follicles, which may be partially or totally covered by the thickened conjunctiva.

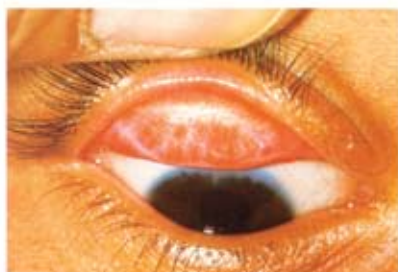

*Trachomatous inflammation – follicular and intense (TF + TI).*

B

**TRACHOMATOUS SCARRING (TS):** the presence of scarring in the tarsal conjunctiva.

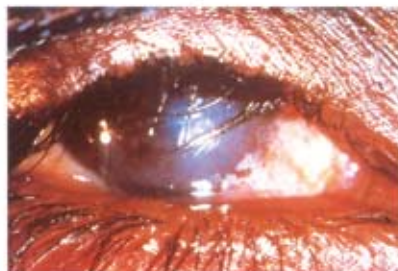
Scars are easily visible as white lines, bands, or sheets in the tarsal conjunctiva. They are glistening and fibrous in appearance. Scarring, especially diffuse fibrosis, may obscure the tarsal blood vessels.



*Trachomatous scarring (TS)*

**TRACHOMATOUS TRICHIASIS (TT):** at least one eyelash rubs on the eyeball.

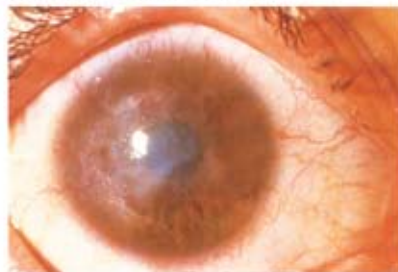Evidence of recent removal of inturned eyelashes should also be graded as trichiasis.



*Trachomatous trichiasis (TT)*

**CORNEAL OPACITY (CO):** easily visible corneal opacity over the pupil.

The pupil margin is blurred viewed through the opacity. Such corneal opacities cause significant visual impairment (less than 6/18 or 0.3 vision), and therefore visual acuity should be measured if possible.



*Corneal opacity (CO)*

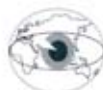**TF:**— give topical treatment (e.g. tetracycline 1%).

**TI:**— give topical and consider systemic treatment.

**TT:**— refer for eyelid surgery.



**WORLD HEALTH ORGANIZATION  
PREVENTION OF BLINDNESS AND DEAFNESS**



Support from the partners of the WHO Alliance for the Global Elimination of Trachoma is acknowledged.

